

Available online at www.sciencedirect.com

ScienceDirect

journal homepage: <http://www.elsevier.com/locate/poamed>

Case Report

Teratoma of the hepatic hilum. Report of a rare case

Grażyna Poniadowska-Broniek^{a,b,*}, Tomasz Siwko^a, Magdalena Misiukiewicz-Poć^b,
Wojciech Choiński^c, Marian Sulik^b

^a Department of Pathomorphology, Regional Children's Specialist Hospital in Olsztyn, Poland

^b Department of Pathology, Faculty of Medical Science, University of Warmia and Mazury in Olsztyn, Poland

^c Department of Pediatric Surgery, Regional Children's Specialist Hospital in Olsztyn, Poland

ARTICLE INFO

Article history:

Received 4 December 2013

Received in revised form

8 April 2014

Accepted 15 April 2014

Available online 15 May 2014

Keywords:

Teratoma

Hepatic hilum

Liver

Abdominal pain

Abdominal cyst

ABSTRACT

Introduction: Teratoma is a rarely occurring neoplasm characterized by an abnormal growth of tissues deriving from three germinal layers: endoderm, mesoderm and ectoderm. Liver is a very rare site for teratoma, as only 28 hepatic teratomas were reported, including 21 in children. Furthermore, teratoma of the liver accounts for less than 1% of all hepatic neoplasms and the majority of these cases occurred in female children below the age of three. Hence, our case is particularly unique.

Aim: The aim of this paper was to report a rare case of a teratoma of the hepatic hilum.

Case study: We report a case of a 12-year-old boy suffering from abdominal pain since the age of 2. Medical imaging revealed an abdominal cyst and after the surgery and histological examination mature teratoma of the hepatic hilum was diagnosed.

Results and discussion: Hilum is particularly unique localization for a liver teratoma, as so far only one such case has been reported. The histology showed a mixture of mature tissues, and no immature elements were found. Thus, histology was typical for *Teratoma maturum*.

Conclusions: The case described here represent a rare case of hepatic teratoma with particularly unique localization in the hepatic hilum.

© 2014 Warmińsko-Mazurska Izba Lekarska w Olsztynie. Published by Elsevier Urban & Partner Sp. z o.o. All rights reserved.

1. Introduction

Teratomas are rarely occurring neoplasms characterized by an abnormal growth of tissues deriving from three germinal layers (endoderm, mesoderm and ectoderm).¹ These tumors do not comprise homogenous histological structures, as they are combinations of tissues, which are unrelated to the organs where the neoplasm originates.²

Teratomas can be categorized as benign or malignant on the basis of their histopathological features.³ A mature teratoma is typically benign, while an immature teratoma is typically malignant. Hence, the presence of immature tissue of any germ layer may affect the prognosis.⁴

The presence of fetal or embryonal hepatoblastoma cells precludes the diagnosis of teratoma,⁵ but about 20% of hepatoblastomas display teratoid features. Thus, it is very important to differentiate them from a true teratoma.

* Correspondence to: Department of Pathomorphology, Regional Children's Specialist Hospital in Olsztyn, Żołnierska 18 a, 10-561 Olsztyn, Poland. Tel.: +48 89 539 32 97.

E-mail address: grazynabroniek@wp.pl (G. Poniadowska-Broniek).

However, a single case of a discrete cystic teratoma contiguous to a hepatoblastoma has been described.⁶

These tumors mostly occur in the ovaries and less frequently in the testes, whereas sacrococcygeal teratomas are most common in children.³ There have been rare cases of this neoplasm occurring in the gastrointestinal tract. An example of such atypical neoplasm is hepatic teratoma accounting for less than 1% of all hepatic neoplasms⁷ and so far only 28 of such cases have been published.^{2,7-9}

The majority of these cases occurred in female children below the age of 3, mostly arising in the right lobe of liver.⁷ Hence, the case of teratoma of the hepatic hilum in a 12-year-old boy is particularly unique.

2. Aim

This paper aimed at presenting a unique case of a teratoma of the hepatic hilum diagnosed in a 12-year-old boy.

3. Case study

A 12-year-old boy suffering from abdominal pain and diagnosed with a pancreatic cyst was admitted to Regional Children's Specialist Hospital in Olsztyn. The interview with the child's mother revealed that patient had been complaining of pains which required hospitalization since he was 2 years old, but it was believed that they were the result of colick. In spite of an atypical age of this affliction, ultrasound investigation had not been performed. Moreover, the patient suffered from gastrointestinal disorders: diarrhea and constipation. During the patient's stay in the hospital his general condition was good. The child did not complain of any discomfort, had no fever and no loss of appetite.

3.1. Laboratory tests

A series of biochemical tests were performed and all the results, including indicators of liver cell damage, fell within normal

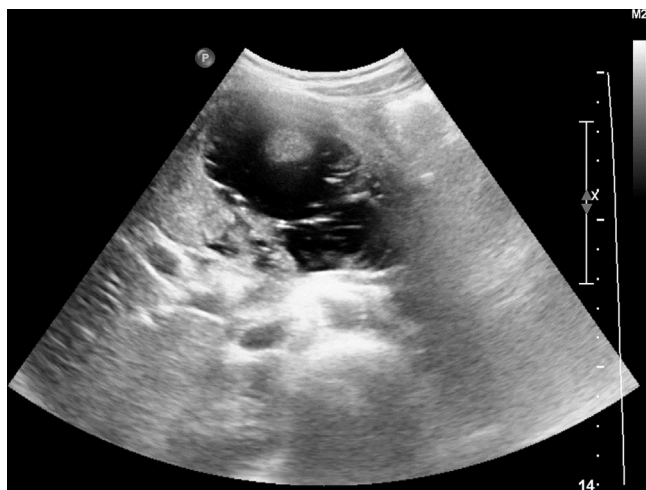

Fig. 1 – Heterogeneous mass (partly solid, partly liquid) at US-scan.

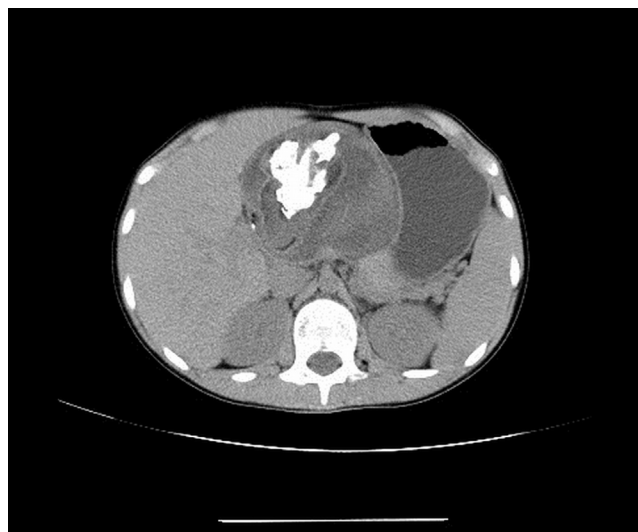

Fig. 2 – Well-defined mass with massive calcifications at CT exam.

ranges: total bilirubin (0.21 mg/dL), gamma-glutamyl transpeptidase (17 U/L), alkaline phosphatase (214 U/L), alanine transaminase (14 U/L) and aspartate transaminase (33 U/L). Complete blood count test and C-reactive protein assay results were normal; thus, no signs of inflammation were revealed.

3.2. Imaging findings

General abdominal ultrasound showed a heterogeneous solid mass located between liver and pancreas, measuring

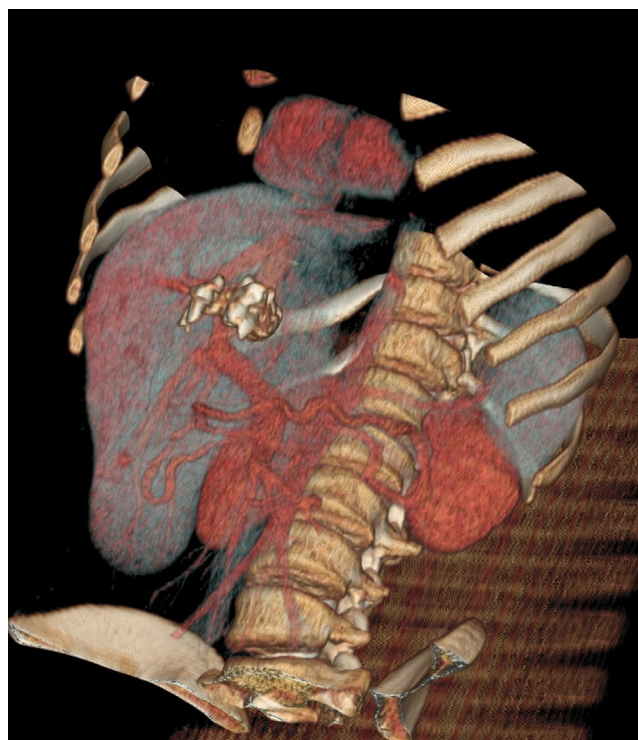


Fig. 3 – The teeth within the mass at CT exam – VR reconstruction.

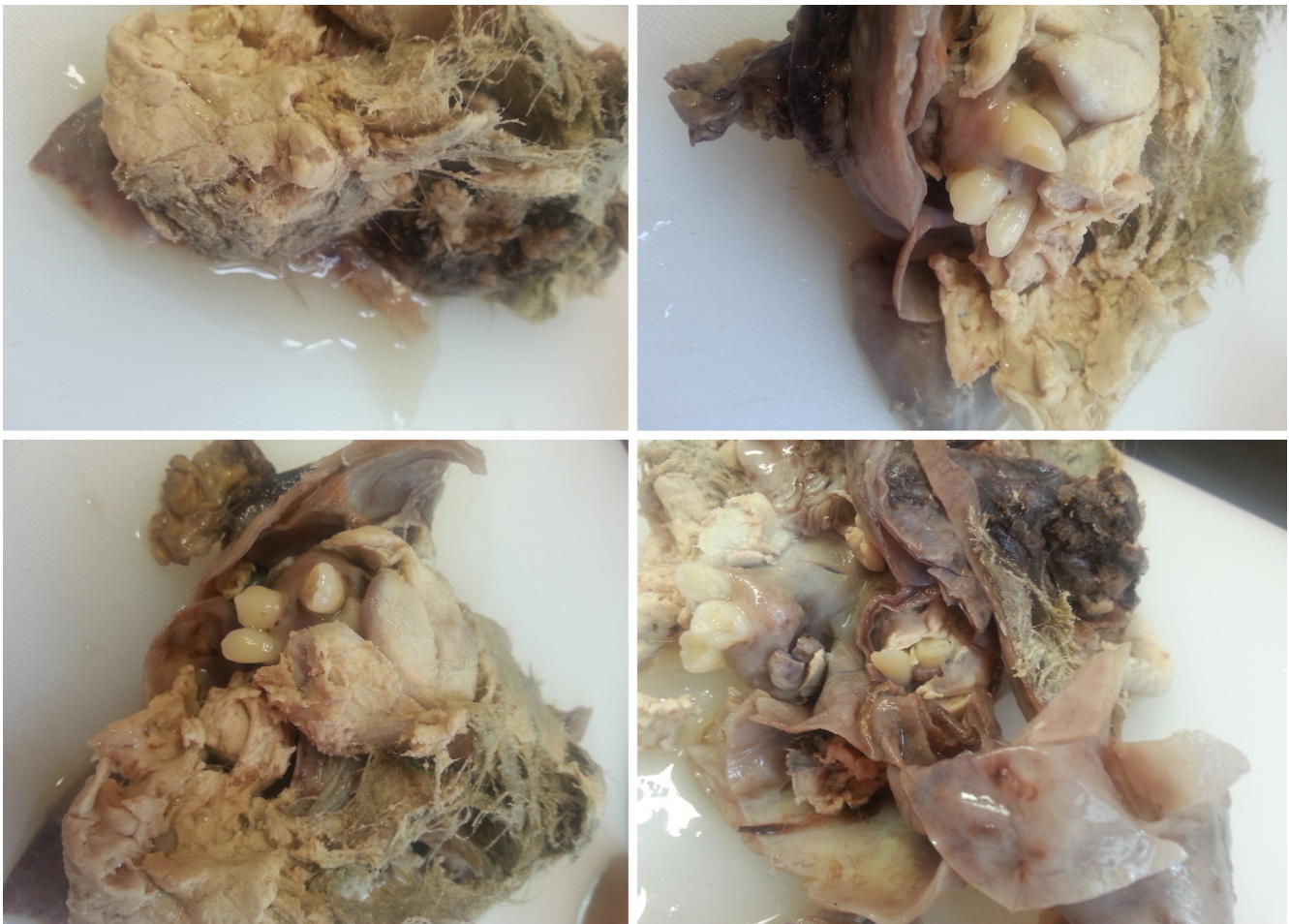

Fig. 4 – Resected tumor with teeth and hair within the sebaceous material.

110 × 81 mm with calcifications (Fig. 1). Overlying gas in the gastrointestinal tract and regions of calcification made it impossible to accurately assess topography and to determine the point of origin of the tumor. Thus, a CT scan was recommended.

Multiphase CT examination of the abdomen was performed before and after the injection of contrast media. The CT scan revealed an oval mass measuring 100 × 94 × 94 mm, located intraperitoneally between the stomach and the left lobe of liver. The tumor was well-defined, with a capsule, which presented post-contrast enhancement. The mass was heterogeneous with central calcification and hypodense areas of fat density (Figs. 2 and 3). Teratoma or fetus in fetu was suspected.

3.3. Surgery

Based on physical examination, the interview with the child's mother, available medical records (medical history and hospital records), imaging (USG and CT scan of abdomen) and laboratory tests, it was decided that laparoscopic surgery for tumor of the hepatic hilum is needed.

Surgery went without any complications although the risk of damaging the blood vessels and the bile duct was high due to localization of the tumor in the hepatic hilum.

The operating surgeons were of the opinion that the mass could represent a teratoma.

3.4. Histopathology

Resected lesion was macroscopically described as well as encapsulated, cystic tumor measuring 100 × 75 × 65 mm. The cyst was filled with sebum, hair and teeth (Fig. 4).

The histology showed a mixture of mature tissues. The cyst wall was partially covered with keratinized stratified squamous epithelium and partially with pseudostratified epithelium (Fig. 5). In the wall of the cyst mature adipose tissue (Fig. 6) and skin appendages with hair (Fig. 7) were seen. Immature component was not found in any of examined sections. The final pathologic diagnosis was a mature cystic teratoma (*Teratoma maturum*) of hepatic hilum.

3.5. Postoperative course

In the following days the symptoms were typical of the early postoperative period. The patient was in good general condition and complained of abdominal pain, particularly on the right side. The abdomen was soft. The patient had no fever.

After a week abdominal pain occurred periodically and was less severe. The wounds healed and the stitches were removed.

On the 14th day after the surgery, the patient did not complain of any symptoms and was discharged home.

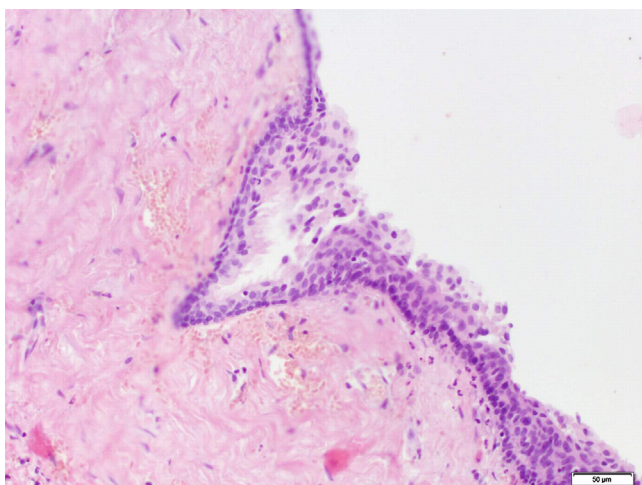


Fig. 5 – Ciliated columnar epithelial cells at photomicrograph (HE, 40×).

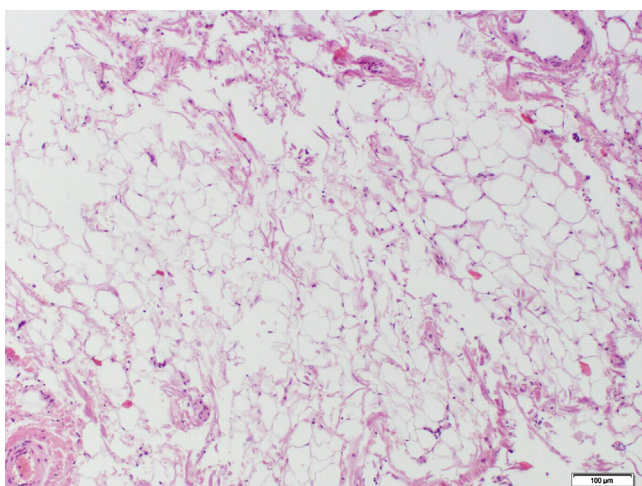


Fig. 6 – Adipose tissue at photomicrograph (HE, 40×).

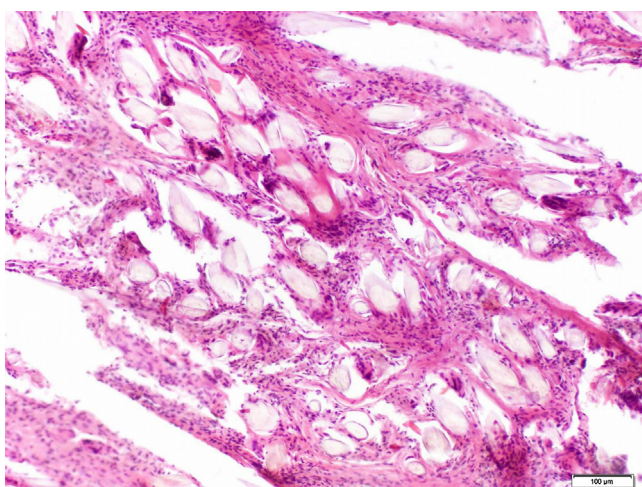


Fig. 7 – Hair shafts at photomicrograph (HE, 40×).

4. Results and discussion

Teratoma is an extremely rare type of liver neoplasm and most of the cases described in literature occurred in female children under the age of 3.⁷ Thus, our case is particularly unique by reason of the gender and the age of the patient and in particular the localization of the tumor.

Based on the interview with the child's mother and morphology of the lesion, we suppose that tumor developed in typical age for teratomas, but it was lately diagnosed.

Teratomas of the hepatic hilums are extremely unique cases. Most of the described hepatic teratomas involved the right lobe of liver.⁷ Less common liver locations include: the left lobe of liver,⁷ pars posterior,⁸ and the falciform ligament of liver.¹⁰ An extensive review of literature yielded only one case of teratoma involving the hepatic hilum.¹¹

The CT scan revealed hypodense areas of fat density, what is considered to be pathognomic of teratomas due to the presence of sebum.^{12,13} However some teratomas do not demonstrate sebum-filled cystic cavity and some cases of mature teratomas had none to minimal fat on radiologic studies.¹⁴

Calcification regions seen on USG imaging and CT scans are also typical for *Teratoma maturum*, but yet again, they may not occur, which makes diagnostic imaging difficult.¹³

Hepatic teratomas are usually well-encapsulated lesions which make them easily resectable from the surrounding hepatic parenchyma.⁷ Our surgeon confirmed that the cyst was well encapsulated; however, its location in the hepatic hilum made the surgery much more difficult due to the high risk of damaging the blood vessels and the bile duct.

Histopathological examination confirmed earlier suspicions. The histology showed a mixture of mature tissues: keratinized stratified squamous epithelium, pseudostratified epithelium, adipose tissue and skin appendages with hair. No immature components were found. Thus, histology was typical of *Teratoma maturum*.

5. Conclusions

1. The case described here represents a rare case of hepatic teratoma with particularly unique localization in the hepatic hilum.
2. Hepatic teratomas are usually well-encapsulated lesions, but its location in the hepatic hilum made the surgery much more difficult due to the high-risk of damaging the blood vessels and the bile duct.

Conflict of interest

None declared.

REFERENCES

1. Winter TC, Freeny P. Hepatic teratoma in an adult. Case report with a review of the literature. *J Clin Gastroenterol.* 1993;17(4):308-310.

2. Certo M, Franca M, Gomes M, et al. Liver teratoma. *Acta Gastroenterol Belg.* 2008;71(2):275-279.
3. Stachura J, Wenancjusz D. *Patologia znaczy słowo o chorobie [Pathology a word about the disease].* Vol. I. Kraków: Polska Akademia Umiejętności; 2008.
4. Souftas V, Polychronidis A, Giatromanolaki A, et al. Dermoid cyst in the hepatoduodenal ligament: report of a case. *Surg Today.* 2008;38(10):959-961. <http://dx.doi.org/10.1007/s00595-007-3744-9>.
5. Stocker JT, Dehner PL, Husain NA. *Pediatric pathology.* Philadelphia: Wolters Kluwer; 2011.
6. Conrad RJ, Gribbin D, Walker NI, et al. Combined cystic teratoma and hepatoblastoma of the liver. Probable divergent differentiation of an uncommitted hepatic precursor cell. *Cancer.* 1993;72(10):2910-2913.
7. Rahmat K, Viayananthan A, Abdullah BJJ, et al. Bening teratoma of the liver: a rare cause of the cholangitis. *Biomed Imaging Interv J.* 2006;2(3):e20. <http://dx.doi.org/10.2349/bijj.2.3.e20>.
8. Gupta R, Bansal K, Manchanda V, et al. Mature cystic teratoma of liver. *ASP J Case Rep.* 2013;4(2):13.
9. Karlo C, Leschka S, Dettmer M, et al. Hepatic teratoma and peritoneal gliomatosis: a case report. *Cases J.* 2009;2:9302. <http://dx.doi.org/10.1186/1757-1626-2-9302>.
10. Ayyappan AP, Singh SE, Shah A. Mature cystic teratoma in the falciform ligament of the liver. *J Postgrad Med.* 2007;53(1):48-49.
11. Dong Q, Jiang B, Lu Y, et al. Surgical management of giant liver tumor involving the hepatic hilum of children. *World J Surg.* 2009;33(7):1520-1525. <http://dx.doi.org/10.1007/s00268-009-0060-0>.
12. Davidson AJ, Hartman DS, Goldman SM. Mature teratoma of the retroperitoneum: radiologic, pathologic and clinical correlation. *Radiology.* 1989;172(2):421-425.
13. Pakdirat B, Prachaphinyo T, Pakdirat P. Radiology of retroperitoneal cystic teratoma in adult: a case report. *J Med Assoc Thai.* 1994;77(5):271-274.
14. Occhipinti KA, Frankel SD, Hricak H. The ovary: computed tomography and magnetic resonance imaging. *Radiol Clin North Am.* 1993;31(5):1115-1132.