

Available online at [www.sciencedirect.com](http://www.sciencedirect.com)

ScienceDirect

journal homepage: <http://www.elsevier.com/locate/poamed>

## Case Report

# Giant metanephric adenoma, benign tumor with features of clinical and radiological malignancy

Janusz Godlewski<sup>a,b,\*</sup>, Konrad Wroński<sup>c,d</sup>, Maciej Michalak<sup>e</sup>,  
Zygmunt Koziół<sup>f</sup>

<sup>a</sup> Department of Human Histology and Embryology, University of Warmia and Mazury in Olsztyn, Poland

<sup>b</sup> Department of Physiotherapy, Jozef Rusiecki University College in Olsztyn, Poland

<sup>c</sup> Department of Surgical Oncology, Ministry of Internal Affairs Hospital with Warmia and Mazury Oncology Centre, Olsztyn, Poland

<sup>d</sup> Department of Oncology, Faculty of Medical Sciences, University of Warmia and Mazury in Olsztyn, Poland

<sup>e</sup> Department of Radiology, Faculty of Medical Sciences, University of Warmia and Mazury in Olsztyn, Poland

<sup>f</sup> Department of Pathomorphology, Faculty of Medical Sciences, University of Warmia and Mazury in Olsztyn, Poland

## ARTICLE INFO

## Article history:

Received 5 November 2014

Received in revised form

5 March 2015

Accepted 9 April 2015

Available online 11 May 2015

## Keywords:

Benign kidney tumor

Metanephric adenoma

Immunohistochemistry

CD57

WT1

## ABSTRACT

**Introduction:** Metanephric adenoma (MA) is a rare benign neoplasm, accounting for 0.2% of adult renal epithelial neoplasms. This neoplasm mainly occurs in patients aged 50–60 years.

**Aim:** The aim of this study was presentation of rare kidney tumor assessment to elaborate proper postoperative decisions and further patient's recommendation.

**Material and methods:** The case of a 64-year-old woman with MA is presented. Radiological, intraoperative and pathomorphological evaluations of this neoplasm were performed and compared.

**Results and discussion:** Primarily performed CT imaging analyzed this tumor as a malignant neoplasm; organ destruction and evident mass invasion in the calyx and kidney pelvis region were noticeable. Regardless of the initial radiological and clinical characteristic, postoperative pathomorphological analyses recognized the benign nature of this tumor; regularly located tubules and small cell regular outlook were observable. Attention was given to a solid fibrous capsule, which separated neoplasm from the rest of the healthy kidney structure. The patient was not qualified for adjuvant therapy, based on the pathomorphological evaluation due to characteristic nature of the benign kidney tumor. Nevertheless, in view of the initial observations (radiological and clinical) and because cases of metastases in the course of MA are described in the literature, a further periodic follow-up was strongly suggested to the patient.

**Conclusions:** The evaluation of neoplasm tumor requires many analyses. In this rare tumor lack of correlation was observed between radiological and pathomorphological examinations. The clinical decision connected with the patient's recommendation should be based on complete results, especially pathomorphological diagnosis. The patient is now under

\* Correspondence to: Department of Human Histology and Embryology, University of Warmia and Mazury in Olsztyn, Warszawska 30, 10-900 Olsztyn, Poland. Tel.: +48 698 694 528.

E-mail address: [janusz350@poczta.onet.pl](mailto:janusz350@poczta.onet.pl) (J. Godlewski).

clinical observation and in six months follow-up has had no neoplasm recurrence or metastasis.

© 2015 Warmińsko-Mazurska Izba Lekarska w Olsztynie. Published by Elsevier Sp. z o.o. All rights reserved.

## 1. Introduction

Metanephric adenoma (MA) is a rare benign neoplasm, accounting for 0.2% of adult renal epithelial neoplasms.<sup>1</sup> This neoplasm mainly occurs in patients aged 50–60 years.<sup>2–4</sup> The incidence of this tumor is two times higher in women than in men.<sup>4</sup> MA is qualified as a benign neoplasm, but few cases of metastases in the course of this disease have been reported.<sup>5,6</sup> We describe the case of a giant MA. This tumor in computer tomography (CT) imaging, and in clinical evaluation, has strong malignancy features although postoperative pathomorphological results indicated the benign nature of this neoplasm.

## 2. Aim

The aim of this study was presentation of a neoplasm tumor characteristic to make appropriate evaluation and determine its exact nature, in purpose to create proper clinical decision, and offer or decline postoperative adjuvant treatment and follow-up for patient. The neoplasm specific features, based on preoperative radiological assessment, intraoperative examination and pathomorphological analyses, were demonstrated.

## 3. Case study

A 64-year-old woman was referred to the Surgical Oncology Department of the Warmia and Mazury Oncological Centre in

Olsztyn due to an incidentally diagnosed giant kidney tumor. It was initially estimated by USG examination and a CT examination was subsequently performed. CT scanning confirmed a solid kidney tumor measuring about 105 mm × 100 mm in maximal transverse dimension. Neoplasm was located in the upper part of the kidney parenchyma and protruded to the surrounded fat tissue without infiltration of the renal vascular pedicle or adjacent organs (Fig. 1). There were no noticeable metastases to the abdominal organs or lymphadenopathy.

The patient has no clinical symptom of illness, no pain in the left area of kidney or any other symptoms and there was no history of weight or appetite loss. She had an operation on a cerebral aneurysm 30 years ago. There was no history of kidney carcinoma in her family, although her brother suffers from prostate carcinoma. On physical examination, the abdomen was soft, painless, without peritoneal symptoms and the tumor was also unpalpable. The performed routine hematological examinations and biochemical tests were within normal limits: the hemoglobin level was 132 g/L, the red blood cell count –  $4.85 \times 10^{12}$  U/L, creatinine level –  $77.8 \mu\text{mol/L}$ , and GFR –  $1.08 \times 10^{-3}$  L/s.

Due to the large size of the tumor and infiltration of renal pelvis region, there was a suspicion of malignant neoplasm and radical kidney resection was advised. During the operation, a tumor located on the upper part of the kidney was confirmed and radical nephrectomy was performed. The patient felt good and did not complain directly after surgery. The postoperative period was uncomplicated and the patient left the ward on the seventh day following surgery.

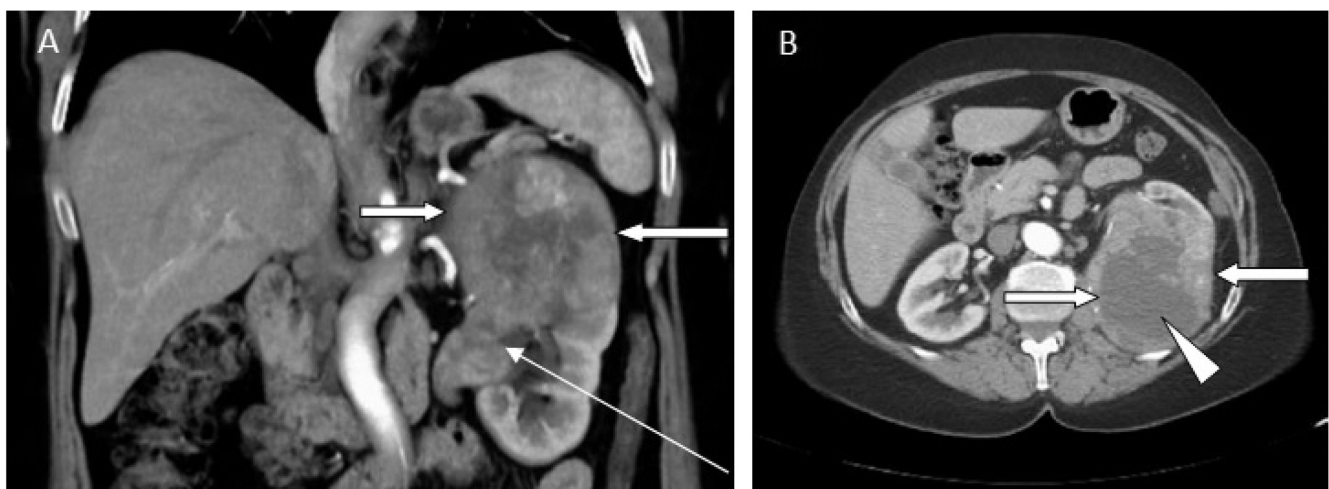
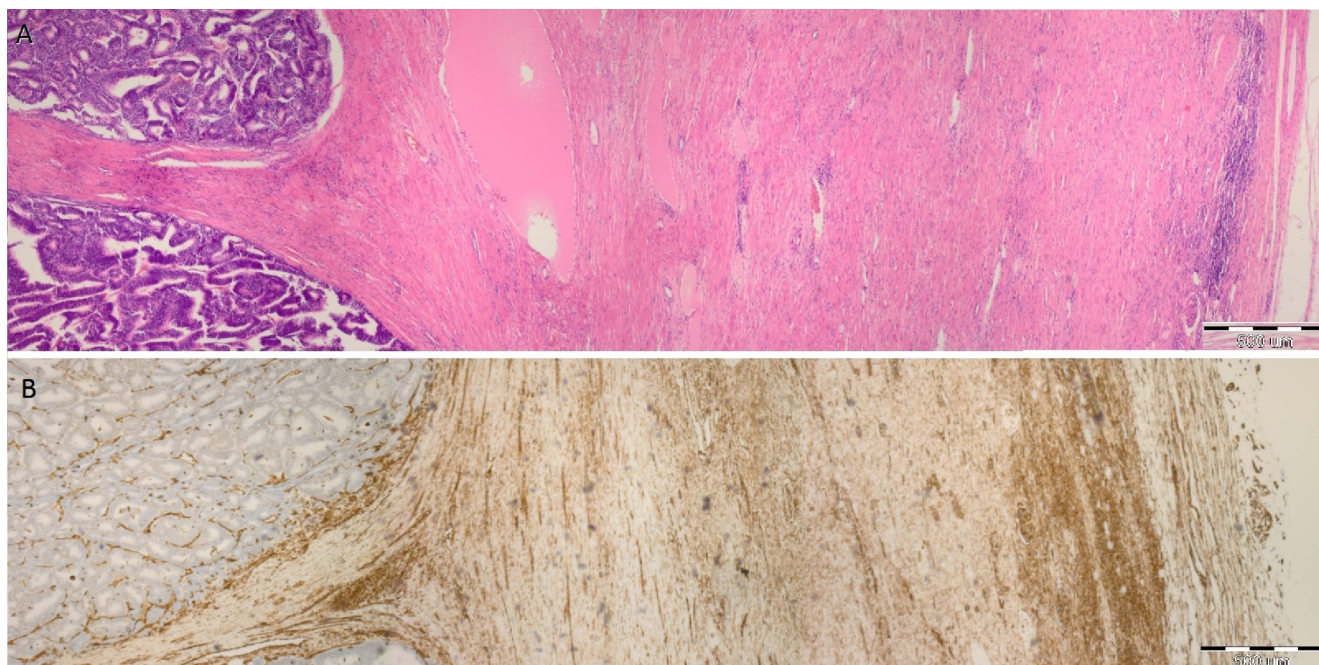


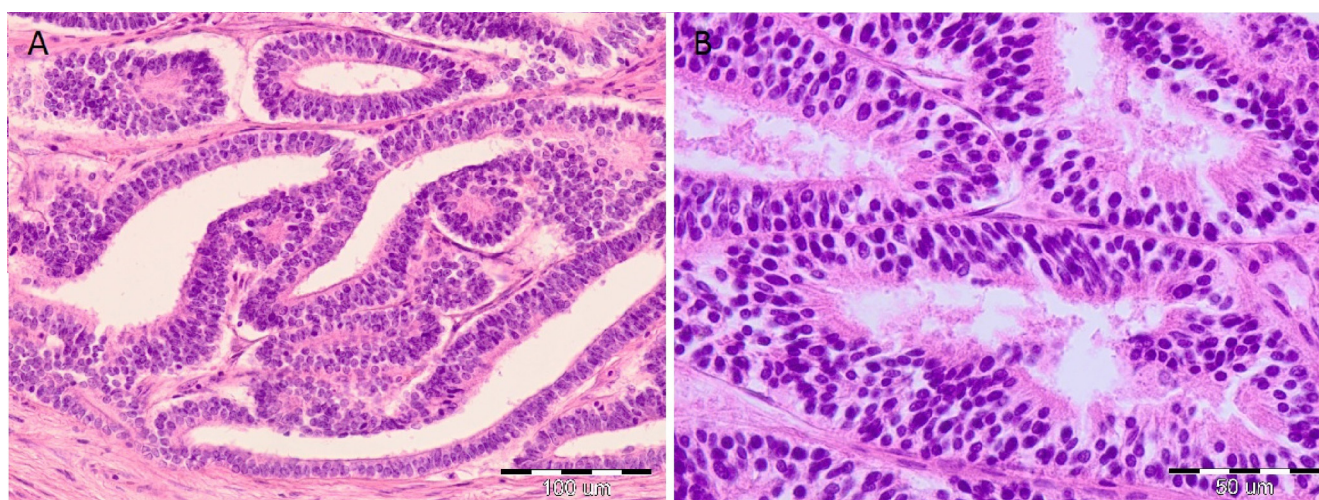
Fig. 1 – Localization of solid tumor in CT scan after intravenous injection of iodinated contrast. (A) Coronal plane, solid tumor in upper part of the left kidney (thick arrows) is visible; the tumor protrudes outside the organ and infiltrates the calyx and renal pelvis to the level of uretero-pelvic junction (thin arrow); (B) axial plane, the tumor (thick arrow) with central necrosis (triangle) is evident.



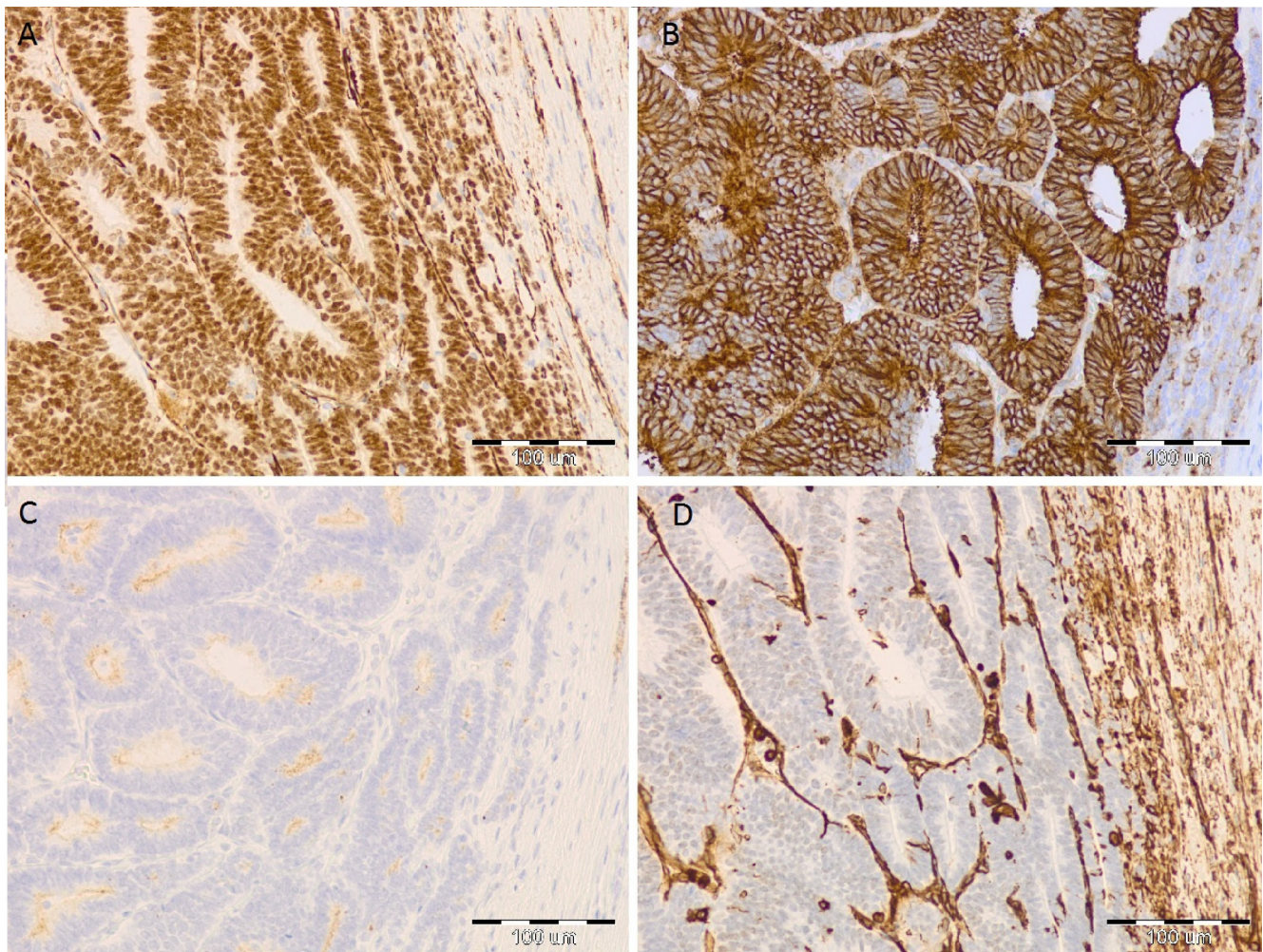
**Fig. 2 - Photomicrography of the tumor (magnification 40×). (A) Thick, solid tumor capsule composed from compact stratum of collagen fibers (HE staining). (B) Vimentin presence (which demonstrate the intermediate filament of fibroblast), positive dyeing in the capsule that was built up from thick layer of compact connective tissue (IHC staining).**

Pathomorphological analyses established that tumor at the cross-section had evident capsule as well as parenchyma central degradation. The mass of tumor was also found in renal pelvis. Microscopic observations established that the solid fibrous capsule clearly separated tumor tissues mass from the rest of the healthy kidney structure (Fig. 2). Additionally, compression of the peripheral part of adenoma's pseudo-tubules/acini just in the vicinity of the fibrous capsule

as well as the squeezing of the regular tubules and the glomerules of normal kidney just outside the margin of the capsule were clearly visible (Fig. 3). In the IHC staining, this MA had typical immunoreactivity characteristic for antigens panel (Fig. 4): positive reaction to cluster of differentiation 57 (CD57) and Wilms tumor protein (WT1) as well as negative reaction to alpha-methylacyl-CoA racemase (AMACR) and cytokeratin 7 (CK7).



**Fig. 3 - Photomicrography of the tumor (HE staining). (A) The morphological structure of metanephric adenoma, well circumscribed tumor with solid capsule is visible. Tumor is composed from densely packed pseudo-tubules/acini. (B) Adenomas pseudo-tubules/acini are composed from small cells that are located in a stratified manner with minimal amount of cytoplasm, distinct nucleuses and an absence of mitotic figures that were noticeable.**



**Fig. 4 – Immunoreactivity characteristic for antigens panel (IHC staining). (A) Nuclear reaction with WT1 antibody in the adenoma cells is visible. (B) Strong cytoplasmatic reaction with CD57 antibody is evident. (C) Lack of reaction with AMACR antibody. (D) Negative reaction with vimentin antibody within adenoma cells is visible.**

#### 4. Results

The patient was not recommended for additional treatment, such as adjuvant chemotherapy, because a pathomorphological diagnosis had indicated the benign nature of this kidney tumor. Furthermore, due to initial observations (radiological and clinical) and because cases of metastases in the course of MA are described in the literature, a further periodic follow-up was strongly recommended to the patient. The patient is now under the care of the urological outpatient clinic at our Oncological Centre and in a follow-up examination no recurrence or metastasis was observed after six months.

#### 5. Discussion

The kidney tumors may be diagnosed incidentally in asymptomatic stadium of illness usually during USG examination.

USG assessment is initially used to differentiate kidney tumor as a cyst or solid mass and to measure it.<sup>7</sup> Contemporary CT scanning is considered as a basic standard in radiological diagnostics in kidney tumor evaluation and helps surgeons to make treatment decisions. This examination is essential for confirmation of tumor and making precise measurements.<sup>8</sup> Moreover, it is used to determine visible malignancy features, such as central tumor disintegration or necrosis, abdominal lymph node enlargement, adjacent organ invasion, close and distal metastases presence as well as occurrence of thrombosis in vena cava.<sup>9</sup> In a radiological assessment, this described mass met some of the above-cited criteria for the diagnosis of the malignant nature of the tumor. Furthermore, in a CT scan, this tumor with a 10.5 cm diameter was much bigger than compared to the mean MA size of 5.5 cm described by others.<sup>10</sup> Kidney tumors are mostly malignant and mass size is the strongest predictor of malignancy – it has been claimed that 23.3% of tumors smaller than 4 cm are benign, but only 8% of tumors larger than this size are non-malignant.<sup>11</sup> Additionally,

according to the literature, MA is described in CT scans as a hyperattenuating mass in comparison with the rest of the organ. The large tumors are heterogeneous, hypovascular masses, attenuating in the central part as central necrosis. Calcifications are noticeable in 20% of tumors.<sup>12,13</sup> The contemporary recommendation for the choice of treatment in incidentally discovered solid mass management is small tumor percutaneous ablation or partial nephrectomy, as well as total nephrectomy in the case of a large tumor.<sup>14–16</sup> According to the literature sources, MA is considered as a benign tumor. It has been described (for a review, see Kuroda<sup>17</sup>) as a well-circumscribed mass and some tumors have visible fibrous capsules. The tumor at the cross-section has a tan, gray or yellow color, with cysts, calcified spots and also hemorrhage or necrosis focuses. In microscopic observations, adenomas are generally built up from tightly packed acini or tubules and glomeruloid bodies are also present. The tumor cells are generally small and have a minimal amount of cytoplasm with round or oval nucleuses.<sup>17,18</sup> The fibrous capsule is a characteristic feature of the benign tumors. The infiltration visible in this case in the calyx and kidney pelvis region may be associated with higher activity of proteolytic enzymes – metalloproteinases – which is distinctive for malignant neoplasm invasion.<sup>19</sup>

Due to possible similarity of MA neoplasm's architectures on comparing to some cases of papillary renal cell carcinoma (PRCC) as well as epithelial type of Wilms' tumor morphology, it is crucial to diversify these types of tumors in the course of pathomorphological evaluation. IHC staining allows distinguishing MA benign tumor from these two kidney malignant neoplasms. MA tumor has to be positive for CD57 and WT1 as well as negative to CK7 and AMACR. Positive staining for CK7 and AMACR is useful to identify PRCC and helps to confirm this malignant neoplasm character. Moreover the Wilms' tumor shows CD57 negative immunoreactions and this way MA could be differentiated in case of WT1 positive staining in investigated tissue samples.<sup>20,21</sup>

## 6. Conclusions

The evaluation of the neoplasm tumor's exact nature is a compound process which needs many analyses. Sometimes particular examinations' outcome brings contrary result and conclusion. In this presented case lack of correlation between radiological and pathomorphological examinations was observed. Despite initial assessment the final clinical decision connected with exact recommendation for the patient should be based on complete clinical study, especially pathomorphological diagnosis and staging. The presented patient, at this time, is under clinical observation in purpose to early detection any neoplasm recurrence or metastases.

## Conflict of interest

All authors declare no conflict of interest.

## REFERENCES

1. Amin MB, Amin MB, Tamboli P, et al. Prognostic impact of histologic subtyping of adult renal epithelial neoplasms: an experience of 405 cases. *Am J Surg Pathol.* 2002;26(3):281–291.
2. Burger M, Junker K, Denzinger S, et al. Metanephric adenoma of the kidney: a clinicopathological and molecular study of two cases. *J Clin Pathol.* 2007;60(7):832–833.
3. Renshaw AA, Freyer RD, Hammers AY. Metastatic metanephric adenoma in a child. *Am J Surg Pathol.* 2000;24(4):570–574.
4. Schmelz HU, Stoschek M, Schwerer M, et al. Metanephric adenoma of the kidney: case report and review of the literature. *Int Urol Nephrol.* 2005;37(2):213–217.
5. Pins MR, Jones EC, Martul EV, Kamat BR, Umlas J, Renshaw AA. Metanephric adenoma-like tumors of the kidney: report of three malignancies with emphasis on discriminating features. *Arch Pathol Lab Med.* 1999;123(5):415–420.
6. Nakagawa T, Kanai Y, Fujimoto H, et al. Malignant mixed epithelial and stromal tumors of the kidney: a report of the first two cases with a fatal clinical outcome. *Histopathology.* 2004;44(3):302–304.
7. Sacco E, Pinto F, Totaro A, et al. Imaging of renal cell carcinoma: state of the art and recent advances. *Urol Int.* 2011;86(2):125–139.
8. Kang SK, Chandarana H. Contemporary imaging of the renal mass. *Urol Clin North Am.* 2012;39(2):161–170.
9. Heidenreich A, Ravery V. Preoperative imaging in renal cell cancer. *World J Urol.* 2004;22(5):307–315.
10. Davis Jr CJ, Barton JH, Sesterhenn IA, Mostofi FK. Metanephric adenoma. Clinicopathological study of fifty patients. *Am J Surg Pathol.* 1995;19(10):1101–1114.
11. Frank I, Blute ML, Chevillie JC, Lohse CM, Weaver AL, Zincke H. Solid renal tumors: an analysis of pathological features related to tumor size. *J Urol.* 2003;170(6 Pt 1):2217–2220.
12. Chaudhary H, Raghvendra M, Dubey D, et al. Correlation of radiological and clinical features of metanephric neoplasms in adults. *Indian J Cancer.* 2004;41(1):37–40.
13. Fielding JR, Visweswaran A, Silverman SG, Granter SR, Renshaw AA. CT and ultrasound features of metanephric adenoma in adults with pathologic correlation. *J Comput Assist Tomogr.* 1999;23(3):441–444.
14. Van Poppel H, Becker F, Cadeddu JA, et al. Treatment of localised renal cell carcinoma. *Eur Urol.* 2011;60(4):662–672.
15. Volpe A, Cadeddu JA, Cestari A, et al. Contemporary management of small renal masses. *Eur Urol.* 2011;60(3):501–515.
16. Silverman SG, Israel GM, Herts BR, Richie JP. Management of the incidental renal mass. *Radiology.* 2008;249(1):16–31.
17. Kuroda N, Toi M, Hiroi M, Enzan H. Review of metanephric adenoma of the kidney with focus on clinical and pathobiological aspects. *Histol Histopathol.* 2003;18(1):253–257.
18. *Kidney Tumor – Cysts, Children, Adult Benign. Benign (Usually) Adult Tumors. Metanephric Adenoma.* 2014. <http://www.pathologyoutlines.com/topic/kidneytumor/metanephric.html> [accessed 01.04.14].
19. Kwiatkowski P, Godlewski J, Śliwińska-Jewsiewicka A, Kmiec Z. The role of matrix metalloproteinases in tumor invasion. *Pol Ann Med.* 2008;15(1):66–76.
20. Kuroda N, Tanaka A, Ohe C, Nagashima Y. Recent advances of immunohistochemistry for diagnosis of renal tumors. *Pathol Int.* 2013;63(8):381–390.
21. Olgac S, Hutchinson B, Tickoo SK, Reuter VE. Alpha-methylacyl-CoA racemase as a marker in the differential diagnosis of metanephric adenoma. *Mod Pathol.* 2006;19(2):218–224.